

A701: Test slide, various cancers plus corresponding normal

(Paraformaldehyde fixed)


For research use only

Specification :

- Specimen** : Paraformaldehyde-fixed, paraffin-embedded 1.0mm diameter 12 different types of cancer tissue and matching normal tissue cores. Single spot for each tissue type.
- Packing status** : Each array slide is individually packed in i) a hard plastic case and ii) an opaque aluminum bag sealed under a nitrogen atmosphere to prevent oxidation and drying.
- Enclosed documents**: product specification (specification, layout, coordinates of tissue spots), H&E stained images, general protocols (3 pages).
- 3.5 inch diskette** : This contains a data set related to the tissues on the slide, in MS Excel format.

Storage and handling

Shipped at room temperature. Recommended storage conditions upon arrival: 2-8 °C. Each individually packed aluminum foil envelope has been filled with nitrogen gas. For maximum antigenicity, use the slide as soon as possible after opening.

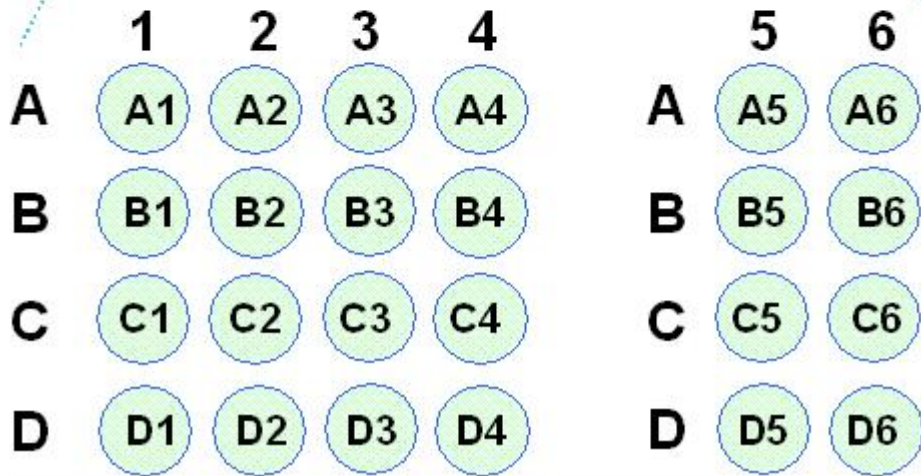
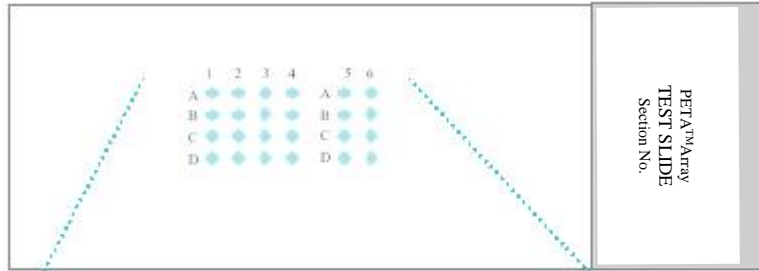


A701: Test slide, various cancers plus corresponding normal

(Paraformaldehyde fixed)

For research use only

Layout



A701: Test slide, various cancers plus corresponding normal

(Paraformaldehyde fixed)

For research use only

Coordinates of tissue spot

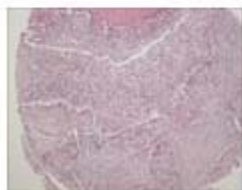
No.	Coordinate	Age	Sex	Tissue Type	Pathology diagnosis
1	A 1	29	m	Skin	Squamous cell carcinoma
2	B 1	29	m	Skin	Normal
3	A 2	48	f	Breast	Ductal carcinoma
4	B 2	48	f	Breast	Normal
5	A 3	32	f	Thyroid gland	Follicular carcinoma
6	B 3	32	f	Thyroid gland	Normal
7	A 4	69	m	Lung	Squamous cell carcinoma
8	B 4	69	m	Lung	Normal
9	A 5	29	f	Liver	Hepatoma
10	B 5	29	f	Liver	Normal
11	A 6	58	f	Kidney	Renal cell carcinoma
12	B 6	58	f	Kidney	Normal
13	C 1	45	m	Bladder	Transitional cell carcinoma
14	D 1	45	m	Bladder	Normal
15	C 2	34	f	Ovary	Serous carcinoma
16	D 2	34	f	Ovary	Fallopian tube
17	C 3	33	f	Uterus	Cervix carcinoma
18	D 3	33	f	Uterus	Normal
19	C 4	64	m	Esophagus	Squamous cell carcinoma
20	D 4	64	m	Esophagus	Normal
21	C 5	67	m	Stomach	Signet ring cell carcinoma
22	D 5	67	m	Stomach	Normal
23	C 6	70	m	Colon	Adenocarcinoma
24	D 6	70	m	Colon	Normal

A701: Test slide, various cancers plus corresponding normal

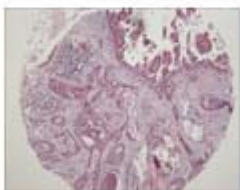
(Paraformaldehyde fixed)

For research use only

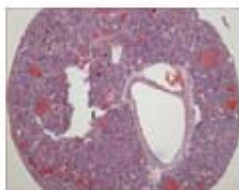
QC sheet_LOT#13101200304191
Haematoxylin and Eosin staining



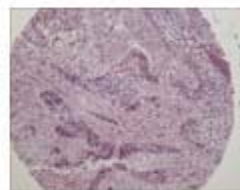A1



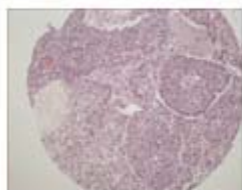
A2



A3



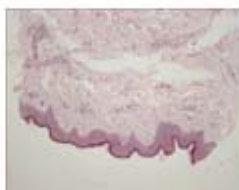A4



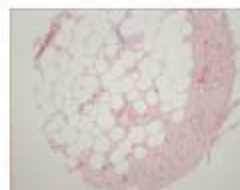
A5



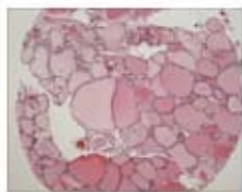
A6



B1



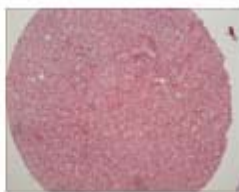
B2



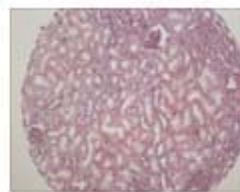B3



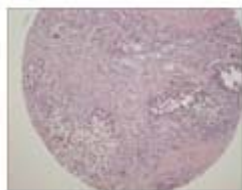
B4



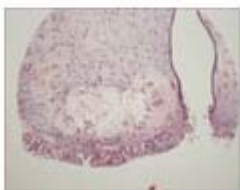B5



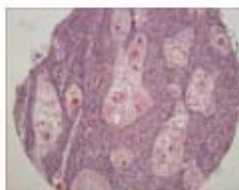
B6



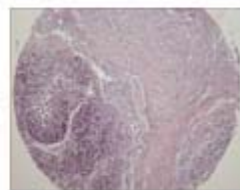
C1



C2



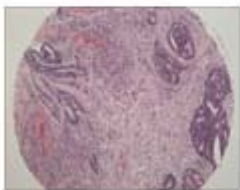C3



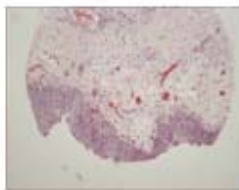
C4



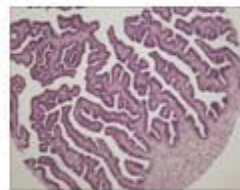
C5



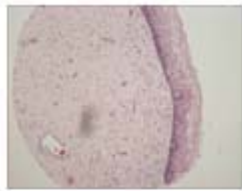
C6



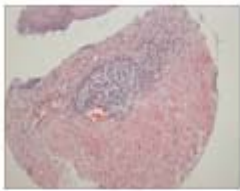
D1



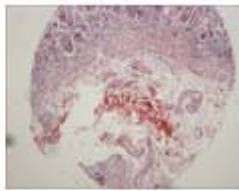
D2



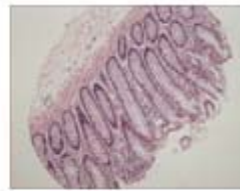D3



D4



D5



D6

A701 : test slide, various cancers + corresponding normal tissues

No.	Age	Sex	Specimen	Key word	Pathological information
A1 B1*	m	29	skin	invasive squamous cell carcinoma	<p>Skin, scalp, excision:</p> <ol style="list-style-type: none"> 1. Invasive squamous cell carcinoma, well-differentiated with extension to the subcutaneous fat tissue (invasion depth: about 3cm). 2. Resection margins, all circumference and base: Free of tumor. 3. Lymph nodes, level 2a(0/36), level 2b(0/11), level III(0/25), level IV(0/13) and level V(0/11):(0/96): Free of tumor.
A2 B2*	f	48	breast	infiltrating ductal carcinoma	<p>Breast, right, modified radical mastectomy:</p> <ol style="list-style-type: none"> 1. Infiltrating ductal carcinoma <ol style="list-style-type: none"> 1) Black's nuclear grade 1 (poorly differentiated). 2) Modified Bloom and Richardson's histological grade III (tubule formation:3, nuclear pleomorphism:3, mitosis:2). 3) No vascular invasion. 2. Regional lymph node, axillary(0/18), level III(0/5):(0/23): Free of tumor. <p>Note: ER(+), PR(+), C erb B2(-).</p>
A3 B3*	f	32	thyroid	follicular carcinoma	<p>Thyroid gland, right, thyroidectomy:</p> <p>Follicular carcinoma, minimally invasive, showing capsular invasion.</p>
A4 B4*	m	69	lung	<ol style="list-style-type: none"> 1. squamous cell carcinoma 2. obstructive pneumonitis 3. pneumonia 	<p>Lung, right, pneumonectomy:</p> <ol style="list-style-type: none"> 1. Upper lobe: Squamous cell carcinoma, moderately differentiated, with - extension to the visceral pleura. <ul style="list-style-type: none"> - marked central necrosis. - tumor size: 6.3x5.5cm. - obstructive pneumonitis in the remaining lung. 2. Regional lymph nodes: Free of tumor in all nodes(0/13), in detail, subcarinal(0/6), lower paratracheal(0/2), regional(0/5).

A701 : test slide, various cancers + corresponding normal tissues

No.	Age	Sex	Specimen	Key word	Pathological information
A5 B5*	f	29	liver	hepatocellular carcinoma	Liver, right, lobectomy: Hepatocellular carcinoma, with 1) size: 8x7.6x7.5cm 2) Edmondson grade II 3) macrotrabecular and pseudoglandular types 4) infiltrative type 5) capsular invasion 6) necrosis: less than 5% of total volume 7) portal vein invasion 8) intact hepatic resection margin 9) Non-neoplastic liver showing congestion
A6 B6*	f	58	kidney	renal cell carcinoma	Kidney, left, radical nephrectomy: 1. Renal cell carcinoma, conventional(clear cell) type, with 1) Fuhrman's nuclear grade: 4 2) Foci of sarcomatoid differentiation 3) Invasion to the perinephric fat tissue but not to Gerota's fascia 4) Renal vein involvement (pT3b) 2. Lymph nodes, perihilar(0/11), paraaortic(0/2) and left common iliac(0/3): Free of tumor metastasis in all 16 nodes.
C1 D1*	m	45	bladder	urothelial carcinoma	Urinary bladder including prostate, seminal vesicle and ureter, radical cystectomy: Urinary bladder: Papillary urothelial carcinoma, high grade, with squamous differentiation, with various pathologic state including low grade papillary urothelial carcinoma, urothelial tumor of low malignant potential, carcinoma in situ and papilloma, with extension to the perivesical soft tissue and prostate, and with extensive lymphatic, venous and perineural invasion, incompletely excised.
C2 D2*	f	34	ovary	serous tumor borderline malignancy	Ovary and fallopian tube, side unstated, salpingoophorectomy: Ovary: Borderline serous and mucinous tumor with serous micropapillary pattern (so called micropapillary serous adenocarcinoma by Kurman), confined within ovarian capsule. The matched normal tissue of this case is fallopian tube, not ovary.

A701 : test slide, various cancers + corresponding normal tissues

No.	Age	Sex	Specimen	Key word	Pathological information
C3 D3*	f	33	uterus(cervix)	invasive squamous cell carcinoma	Cervix: Invasive squamous cell carcinoma, large cell, keratinizing (invasion depth: 1.1cm) with focal lymphovascular permeation
C4 D4*	m	64	esophagus	basaloid carcinoma	Esophagus, esophagectomy: Basaloid squamous cell carcinoma with 1) size: 2.7x2.0x2.0cm. 2) expanding growth. 3) involvement at submucosal space and extension to upper border of proper muscle layer. 4) intact proximal and distal resection margin. 5) no tumor metastasis to upper paraesophageal lymph node (separately submitted:0/2)
C5 D5*	m	67	stomach	signet ring cell carcinoma	Stomach, subtotal gastrectomy: 1..Signet ring cell carcinoma 1. Diffuse infiltrative type 2. With extension to serosa and perigastric fat tissue(SE) 3. Frequent lymphatic permeation and perineural invasion 4. Focally mixed with tubular adenocarcinoma, moderately differentiated 5. Mixed type by Lauren's classification and infiltrative type by Ming's classification 2.. Regional lymph nodes, No.3(6/5), No.4(1/1), No.5(0/0), No.6(9/14), No.7(1/9), No.8(0/3), No.12(0/1), No.13(0/3), No.17(0/2):(17/38): Tumor metastasis in 17 out of 38 nodes.
C6 D6*	m	70	colon	adenocarcinoma	1.Sigmoid colon, radial sigmoid colectomy: A. Adenocarcinoma, poorly differentiated, ulceroinfiltrative type with extension to pericolic fat tissue and is very close to lateral margin (about 0.5mm). B. Tubular adenoma with high grade dysplasia. Resection margins, proximal and distal: Free of tumor. 2. Regional lymph nodes, principal(0/7), pericolic(2/22):(2/29): Tumor metastasis in 2 out of 29 lymph nodes.

*: corresponding normal tissues

Deparaffinization and hydration

Dry the slide at 58°C for 1hr or overnight, before deparaffinization (put slides in horizontal position)

- ① Xylene (removal of paraffin) 4 X 10 min
↓
- ② 100% Ethanol (de xylene)
95% Ethanol 1min
95% Ethanol 1min
80% Ethanol 1min
70% Ethanol 1min
↓
- ③ Wash (tap water) until washing is completed (5 min)

Routine H&E stain

- ① Wash (tap water) until washing is completed (5 min)
↓
- ② Hematoxylin (Harris,nucleus staining,over staining) 3 min
↓
- ③ Wash (tap water)
↓
- ④ Decolor in 0.1% HCl, 70% Ethanol : repetitive dipping
↓
- ⑤ Neutralization 10 min (top water 5min/ Ammonia water repetitive dipping)
↓
- ⑥ Eosin (cytoplasm staining) 1 min
↓
- ⑦ Washing 30 sec
↓
- ⑧ 70% Ethanol 1 min
80% Ethanol 1 min
95% Ethanol 1 min
95% Ethanol 1 min
100% Ethanol 1 min
↓
- ⑨ Xylene (clear to increase refractive index to 1.5 fold) 4 X 10 min
↓
- ⑩ Mount with mounting solution (eg. balsam)

IHC(immunohistochemistry)

Immunohistochemistry is an exquisitely sensitive method for locating an antigen within a cell or tissue through a high-resolution image (a single cell among thousands or millions). The method is based on the use of a primary antibody binding specifically to its cognate antigen. The bound antibody is then visualized by colorimetric or fluorescent detection methods.

<p>Antigen retrieval method During the preparation of tissues for staining, antigens are heavily modified by the fixatives frequently on free amino acid groups. Because they can be hidden by other molecules, antigen retrieval procedure is required to counter these changes. There are several methods for antigen retrieval. The selection is made according to the experimental purposes. If the experiment is the conditioning process with first trial of that antibody, various methods need to be tried.</p> <p>1. Proteolytic enzyme pre-treatment method Cleave the bonds formed from the fixation process. Enzymes routinely used include trypsin, pronase or pepsin. The concentration and reaction time must be controlled since the excess enzyme treatment can damage the target antigens.</p> <p>- pronase: 0.05%(W/V) in PBS or - trypsin : 0.05%(V/V) in PBS - pepsin : 0.05%(V/V) in 2N HCl</p> <p>① Incubate in one of the above solutions at RT or 37 °C for 18 min ② Dip in cold DW</p> <p>2. Heat-induced antigen retrieval method Antigens fixed in formalin are hidden by fixative and calcium ions. Chelating or precipitating these calcium ions by specific solutions like citrate buffer, EDTA and EGTA with heating can cleave these bonds.</p> <p>① Place the slides into a rack ② Immerse the slides in citrate buffer* ③ Move the entire container into microwave oven ④ Microwave the slides at maximum watt for 4 X 5 min (after each cycle, replenish any lost liquid from the slide container by addition of DW) ⑤ Remove the container and allow it to cool to RT ⑥ Wash with appropriate washing buffer</p> <p>*citrate buffer : 0.01M citric acid, pH 6.0</p>	<p>IHC procedure The protocol needs to be optimized for antibody you may want to test and/or you might need to follow instructions from suppliers.</p> <p>① Dry a slide at 58 °C overnight ② Deparaffinize in xylene ③ Hydrate the slide in gradient ethanol ④ Retrieve antigen (see left section) ⑤ Dip in 3% H₂O₂ 10-15 min and washing buffer 3 X 5 min ⑥ Block with normal serum</p> <p>1. Direct method</p> <p>⑦ Biotin-tagged Primary Ab for 1~2 hr at RT or 37 °C incubator or for overnight at 4 °C (don't wash, just change the blocking solution for primary antibody) and washing buffer 2 X 5 min</p> <p>2. Indirect method</p> <p>⑦-1. Biotin-tagged primary Ab for 1~2 hr at RT or 37 °C incubator or for overnight at 4 °C (don't wash, just change the blocking solution for primary antibody) and washing buffer 2 X 5 min ⑦-2. Biotin-tagged secondary Ab for 10-15min at RT and washing buffer 2 X 5 min</p> <p>⑧ ABC reagent (streptavidin-HRP) for 10~15min and washing buffer for 2~3 X 5 min ⑨ Fresh chromogen (DAB or AEC) for 1~3 min and Wash with tap water ⑩ Counter stain (the nucleus) with Hematoxylin or methyl green ⑪-1. When Hematoxylin is used : dehydrate in gradient ethanol (70% to 100%) and clear with xylene, mount with insoluble mounting medium (eg. balsam) ⑪-2. When methyl green is used : just dry and mount with soluble mounting medium (eg. glycerin or gelatin) ⑪-3. When AEC is used for chromogen : just dry and mount with soluble mounting medium</p>
--	--

IHC Conditioning

Negative controls without a primary antibody, without a secondary antibody, or without detecting reagents.	
Why does my negative control show strong signal?	The signal is due to non-specific cross-reactivity of detection reagents.
Possible cause of signal	Trouble shooting
<u>Primary Ab only is omitted.</u>	The secondary Ab is binding non-specifically to the tissue. Add 0.1% tissue-specific serum to the secondary Ab.
	Dilute the secondary Ab.
	Change species of secondary Ab.
<u>The secondary antibody only is omitted.</u>	The detecting reagents are binding non-specifically to the tissue. Block tissue with detection reagent.
	Detection reagent only is omitted. Intrinsic tissue enzyme activity is interfering with the reaction. Treat tissue with reaction solution.

Positive controls A positive antibody with the test tissue, or the test antibody with a positive tissue.	
Using an antibody known to react with the test tissue, or using the test antibody with cells known to contain the antigen. Fixatives may have reduced access of the antibody to the antigen. Perform microwave target retrieval procedure or protease digestion.	
Why does my positive control have no signal?	In most cases, this is because the antibody is not optimized or the tissue is not adequately treated.
Possible cause of no signal	Trouble shooting
<u>Ab may be too dilute.</u>	Titrate Ab to determine the optimum dilution that gives the best signal-to-noise ratio.
<u>Secondary Ab does not recognize the primary Ab.</u>	Ensure secondary Ab is directed against the species of primary Ab, e.g. anti-mouse secondary Ab for mouse primary Ab
<u>The enzyme/substrate system is defective or incompatible.</u>	This can be confirmed by performing by dot blot test.